

See discussions, stats, and author profiles for this publication at: <http://www.researchgate.net/publication/26310242>

# Familial Sotos syndrome caused by a novel missense mutation, C2175S, in NSD1 and associated with normal intelligence, insulin dependent diabetes, bronchial asthma, and lipedema

ARTICLE *in* EUROPEAN JOURNAL OF MEDICAL GENETICS · JULY 2009

Impact Factor: 1.49 · DOI: 10.1016/j.ejmg.2009.06.001 · Source: PubMed

CITATIONS

6

DOWNLOADS

32

VIEWS

106

## 8 AUTHORS, INCLUDING:



**Ulrich Zechner**

Johannes Gutenberg-Universität Mainz

137 PUBLICATIONS 2,928 CITATIONS

SEE PROFILE



**Hartmut Engels**

University of Bonn

64 PUBLICATIONS 1,351 CITATIONS

SEE PROFILE



**Thomas Haaf**

University of Wuerzburg

321 PUBLICATIONS 10,888 CITATIONS

SEE PROFILE



**Oliver Bartsch**

Johannes Gutenberg-Universität Mainz

139 PUBLICATIONS 1,435 CITATIONS

SEE PROFILE



## Original article

## Familial Sotos syndrome caused by a novel missense mutation, C2175S, in *NSD1* and associated with normal intelligence, insulin dependent diabetes, bronchial asthma, and lipedema

Ulrich Zechner<sup>a,1</sup>, Nicolai Kohlschmidt<sup>a,1</sup>, Olga Kempf<sup>a</sup>, Konstanze Gebauer<sup>a</sup>, Karsten Haug<sup>b</sup>, Hartmut Engels<sup>b</sup>, Thomas Haaf<sup>a</sup>, Oliver Bartsch<sup>a,\*</sup>

<sup>a</sup>Institute of Human Genetics, Johannes Gutenberg University Mainz, Mainz, Germany

<sup>b</sup>Institute of Human Genetics, University of Bonn, Bonn, Germany

## ARTICLE INFO

## Article history:

Received 27 April 2009

Accepted 7 June 2009

Available online 21 June 2009

## Keywords:

Sotos syndrome

Vertical transmission

*NSD1* mutation

Insulin dependent diabetes mellitus

## ABSTRACT

We report a familial Sotos syndrome in two children, boy and girl, aged 17 and 8 years, and in their 44 year old mother, who displayed normal intelligence at adult age, but suffered from insulin dependent diabetes mellitus, bronchial asthma, and severe lipedema. The underlying missense mutation, C2175S, occurred in a conserved segment of the *NSD1* gene. Our findings confirm that familial cases of SS are more likely to carry missense mutations. This case report may prove useful to avoid underestimation of the recurrence rate of SS, and to demonstrate that the developmental delay may normalize, enabling an independent life and having an own family.

© 2009 Elsevier Masson SAS. All rights reserved.

## 1. Introduction

Sotos syndrome (SS, OMIM 117550) is characterized by pre- and postnatal overgrowth, macrocephaly, typical facial gestalt, large hands and feet, accelerated skeletal age, and developmental delay. Since the first report of this condition in 1964, the diagnosis relied mainly on the clinical phenotype. In 2002, mutations and submicroscopic deletions in the *NSD1* gene at chromosome 5q35 were found in 24 of 42 SS patients [1], enabling molecular genetic diagnosis. Some 50–75% of patients demonstrate mutations in the *NSD1* gene or a microdeletion at chromosome 5q35 [1–4]. *NSD1* encodes the nuclear receptor-binding SET [Su(var)3-9, Enhancer-of-zeste, Trithorax] domain protein 1, which may act as a basic transcriptional factor and bifunctional transcriptional regulator [5]. SET-domain containing proteins (histone lysine methyltransferases) can modify histones and thereby affect gene expression [6].

Today, the Sotos and Weaver syndromes are again thought of as different disorders [4]. For some time it had been proposed that *NSD1* mutations may also cause the overgrowth syndrome of Weaver (OMIM 277590), which is less well defined and much rarer than SS, with only some 20 reported cases to date. Sotos and

Weaver syndromes show overlapping phenotypes, especially at young ages [4,7]. Phenotypic differences include a slightly different facial appearance and more conspicuous contractures in Weaver syndrome and an advanced dental maturation in SS that is rarely observed in Weaver syndrome [7]. In addition, SS has been associated with a slight increased risk for cancer (in particular Wilms tumor), whereas the Weaver syndrome usually is not, although one case of neuroblastoma was reported in Weaver syndrome [7]. When molecular diagnosis became available, it turned out that classic Weaver syndrome is not caused by *NSD1* mutations [2–4].

SS has been associated with a low recurrence risk in sibships and with reduced reproductive fitness. Familial inheritance of SS was first described in 1976 [8]. Since 2003, 16 families have been reported [4,9–11]. In 15 of these families, an *NSD1* mutation or 5q35 microdeletion segregating with the disorder was identified, including seven missense [4,10], four frameshift [4,9], two nonsense [4], and one splice donor site mutation [11]. In one family, the causative mutation was not detected [4]. Familial 5q35 microdeletions were observed in monozygotic twin boys only, but not in families with vertical transmission [4]. Missense mutations appear to be more frequent in familial cases than in sporadic cases [4].

Here we report on a family with SS caused by a novel *NSD1* missense mutation, C2175S. The affected siblings and their likewise affected mother presented with typical facial dysmorphism, macrocephaly, and tall stature. The siblings had characteristic heart defects. The mother had received estrogen/gestagen treatment of

\* Corresponding author. Tel.: +49 6131 17 5791; fax: +49 6131 17 5690.

E-mail address: [bartsch@humgen.klinik.uni-mainz.de](mailto:bartsch@humgen.klinik.uni-mainz.de) (O. Bartsch).

<sup>1</sup> These authors contributed equally to this work.

tall stature as a child and suffered from lipedema, a diabetes that was difficult to manage, and bronchial asthma. Our findings support the idea that *NSD1* missense mutations have a better outcome regarding the intellectual impairment than truncating mutations and microdeletions.

## 2. Subjects

The family was of German origin. Patient 3 and her children (patients 1 and 2) had SS, whereas her husband, parents, brother and nephew were unaffected and healthy. Patient 3 grew up in a family providing excellent support in childhood. Her mother was 170 cm in height (+0.5 SD). Her father had been approximately 180 cm tall (+0.4 SD), German shoe size 46 (UK size 11, US men 11.5–12). He was well-educated and a master butcher in his own shop, but had died already in the 1970s of a horseback riding accident. Her brother was a successful trained retail salesman and approximately 198 cm tall (+3 SD), indicating familial tall stature.

### 2.1. Patient 1

The 10 year old boy (Fig. 1A) was referred to genetic examination by the community pediatrician. He had been delivered by cesarean section at week 36 of gestation after cardiotocogram (CTG) changes had been noticed. Birth weight was 3800 g (+2 SD, 98th percentile) and length 49 cm (+1 SD). His neonatal course was remarkable for prolonged jaundice. An echocardiography revealed an atrioseptal defect (ASD) II. Postnatal growth was accelerated. At age 10<sup>8</sup>/<sub>12</sub> years, he had proportionate tall stature (169 cm [+3.5 SD]); maternal and paternal height were 180 cm each. He had macrocephaly (occipitofrontal circumference [OFC] 57 cm [+2.4 SD]), high frontal hairline, coarse facial features, prominent mandible, high palate, funnel chest, diastasis of the abdominal wall, and large hands and feet (German shoe size 45 [UK size 10.5, US men 11]). Medical problems included mild myopia and allergic rhinoconjunctivitis (hay fever).

Development had been delayed for the first 9 years of his life, with muscular hypotonia and limited gross and fine motor skills, which his mother described as clumsiness. He received physiotherapy from age 3 months and walked at age 23–24 months. After infancy, he had occupational therapy. Intelligence testing at age 6 years indicated an IQ of 100 in the verbal subtests, and 85 in the nonverbal subtests (Wechsler Intelligence Scale for Children, German Adaptation). He had expressive language delay and received speech and language therapy until grade 4. However, he always visited normal schools and completed basic secondary school (German Hauptschule). At age 17 years he was in vocational training as a precision mechanic apprentice. He was 205 cm tall (+4.2 SD) and had large hands and feet, German shoe size 52 (UK size 16, US men 17).

### 2.2. Patient 2

The sister (Fig. 1B, C) of patient 1 was first seen at age 1<sup>5</sup>/<sub>12</sub> years. She had been born at week 30 of gestation after rupture of membranes and abnormal CTG. Birth weight was 1980 g (+1.8 SD) and length 44.5 cm (+1.4 SD). Because of respiratory distress, she received assisted ventilation for 13 days. Echocardiography showed an ASD II. From age 6 months, her motor development was found to be delayed. At age 1<sup>5</sup>/<sub>12</sub> years, she could not sit unsupported for 30 s and showed little interest in toys. Her height was 84.5 cm (+1.6 SD), and weight 13 kg (+1.6 SD). She had macrocephaly (OFC 52.4 cm [+3.9 SD]), a prominent forehead, high frontal hairline, hypertelorism, a small hemangioma under the left eyebrow that was later removed by laser therapy, prominent mandible, pointed

chin, and high palate. She walked at age 23–24 months. At age 4 years, height was 118 cm (+3.5 SD). When last seen at the age of 8<sup>6</sup>/<sub>12</sub> years, height was 152 cm (+3.5 SD), weight 47 kg (+3.5 SD), OFC 59 cm (+4 SD), and German shoe size 40 (UK size 6.5–7, US ladies 8.5–9). She was a shy, lovable, well-adjusted girl making good to average progress in a normal primary school. Medical problems included hay fever and bronchial asthma treated by inhalation therapy.

### 2.3. Patient 3

Patient 3 (Fig. 1D,E), the mother of patients 1 and 2, was first seen as a 36 year old woman. Height was 180 cm (+2.2 SD) after hormonal treatment of tall stature with highly dosed estrogens and gestagens applied by monthly injections from age 9 years to 13 years. She had macrocephaly (OFC 60 cm [ $>3$  SD]), triangular face, sparse hair in the frontoparietal area, coarse facial features, mandibular prognathism, pointed chin, and large hands and feet, German shoe size 46 (UK size 11, US ladies 13.5). She also had chronic lipedema existing since her pre-teen years. Her menarche had occurred at age 9 years.

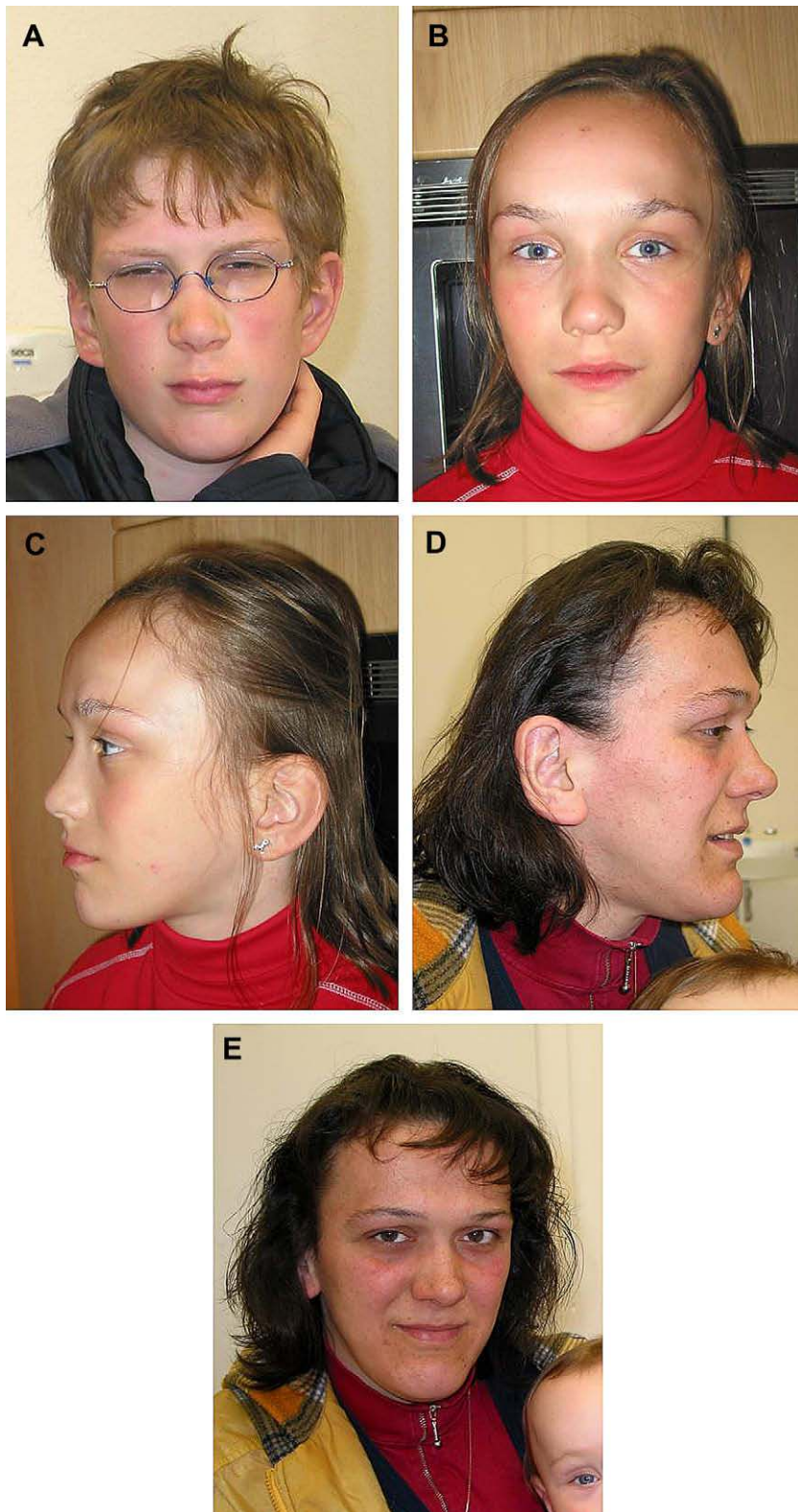
As a child she had received special support and reportedly had been “slow” in elementary school, but then she graduated basic secondary school (Hauptschule) and successfully completed a pastry cook apprenticeship. She had hay fever and bronchial asthma. At the age of 25 years she suddenly felt extremely thirsty and tired, and rapidly lost weight, 10 kg in 4 months. A type 1 diabetes was diagnosed and insulin treatment was initiated. One month later, she became pregnant with her son. In the interval between her two pregnancies, she took anticonvulsives (carbamazepine and valproic acid) for 2 or 3 years because of a suspected epilepsy which was not confirmed later on. When last seen at the age of 44 years, she reported serious medical problems with her diabetes that was difficult to control. She had asthma treated by formoterol inhalation therapy, and lipedema with painful column-like legs and massive accumulations of fat and fluid under the skin of the legs and ankles.

## 3. Cytogenetic and molecular analyses

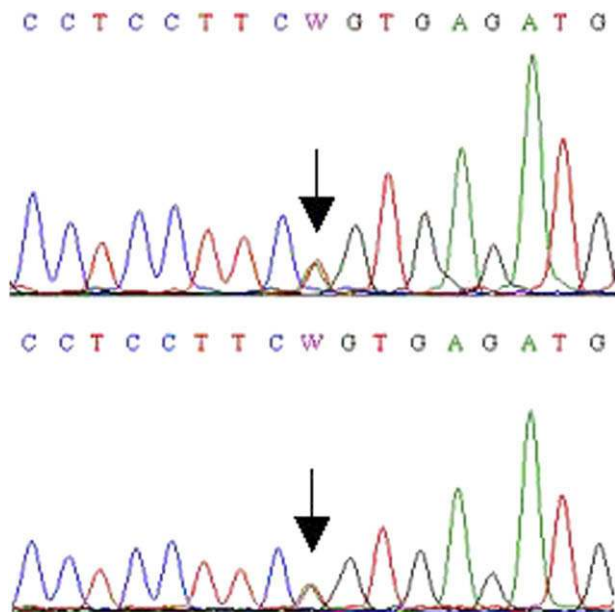
Following detailed genetic counselling, both parents of patients 1 and 2 provided informed consent for genetic analyses. Conventional chromosome analysis (Giemsa banding) on cultured blood lymphocytes of patients 1 and 2 revealed normal 46,XY and 46,XX karyotypes, respectively. *NSD1* microdeletions were ruled out by fluorescent in situ hybridization (FISH) with BAC RP11–118M12, which maps to the critical interval at chromosome 5q35 [1].

Molecular analyses were performed using blood samples from patients 1–3 and from the mother and the brother of patient 3. Genomic DNAs were isolated by a standard salting out procedure. The entire *NSD1* protein-coding region (exons 2–23) was amplified using 31 primer pairs, as described previously [3]. PCR fragments were bidirectionally sequenced using the CEQ™ DTCS Quick Start Kit (Beckman Coulter, Krefeld, Germany) and a Beckman CEQ 8000 Genetic Analysis System.

Two heterozygous alterations were found in the family, both in exon 23; a pathological missense mutation (c.6523T > A, resulting in p.C2175S) (Fig. 2) in all three patients; and a previously reported polymorphism (c.7636G > A, resulting in p.A2546T) [12] in patient 3 and in her mother, but not in patients 1 and 2. The c.6523T > A mutation predicts the exchange of cysteine 2175 to serine in a conserved Cys/His-rich region adjacent to the plant homeo-domain (PHD)-V region which may correspond to another zinc finger-like motif. This cysteine residue is conserved not only in mouse *Nsd1* but also in the two known human *NSD1* paralogues,



**Fig. 1.** Facial appearance (A) of patient 1 aged 10 <sup>8</sup>/<sub>12</sub> years, (B, C) of patient 2 aged 8 <sup>6</sup>/<sub>12</sub> years, and (D, E) of patient 3 aged 36 years, respectively. Note the high frontal hairline and mandibular prognathism as typical signs of the Sotos syndrome.



**Fig. 2.** Electropherograms showing the heterozygous *NSD1* mutation c.6523T > A in patient 2 (top) and patient 3 (bottom). Arrows indicate the base substitution.

*NSD2* and *NSD3*. The c.6523T > A mutation was not found in the mother and brother of patient 3; a sample of her father was not available. The segregation of polymorphism c.7636G > A, which is present in patient 3 and her unaffected mother, but not in patients 1 and 2 indicates that mutation c.6523T > A occurred de novo on the paternally inherited allele of patient 3.

#### 4. Discussion

Familial cases of SS are rare, the majority of cases are sporadic. The two siblings and their mother described here presented with overgrowth and characteristic dysmorphic signs (including macrocephaly, high frontal hairline, coarse facial features, and prominent pointed chin). Genetic testing identified a pathological *NSD1* missense mutation in exon 23 (p.C2175S) in all affected family members. Although the C2175S mutation was not described previously, it is evidently disease-causing because of its position in a conserved domain of the protein. Because a maternally inherited SNP (c.7636G > A) in the same exon (exon 23) did not segregate with the C2175S mutation, the pathogenic mutation must have arisen in the paternally inherited *NSD1* allele of patient 3. Our case supports the observation that the diagnosis of familial SS is usually made via an affected child.

Why are some cases of SS heritable, and what are the predisposing factors? Previous studies [2,4] suggested that familial SS is usually transmitted through the mother, accounting for 75% (12/16) of inherited cases. Here, we present another case of maternal transmission. Our report supports the view that missense mutations – in particular, missense mutations outside the SET domain (position 1941–2063) and the zinc fingers – are more likely to be inherited than truncating mutations or microdeletions [4,10]. Furthermore, our data provide evidence that a subset of individuals with missense mutations may show less severe mental impairment than patients with null mutations. The mutation type seems to play a decisive role in reproductive fitness. Patients with *NSD1* missense mutations outside the SET domain and the zinc fingers may be milder affected and, therefore, demonstrate higher vertical transmission rates.

Höglund et al. [9] described that mental retardation or physical impairment, if present, may affect reproductive fitness as an independent factor. Patient 3 showed poor coordination and expressive language delay during childhood, but normal development at later ages, enabling a normal professional and family life as an adult. Similarly, the motor and language delays of her son (patient 1) decreased during his first years of life. With speech therapy in the first years, he could attend normal school classes enabling a normal professional development. These observations confirm that especially in familial cases of SS, the initial hypotonia and developmental delay may improve during school age. This increases the likelihood of transmitting the mutation to the next generation. Thus, the risk for affected offspring resembles that of other autosomal dominant disorders [9]. Our report underlines the necessity of molecular studies also in the parents and siblings of patients with SS.

Which type of mutation was identified in this family? The 6523T > A mutation in exon 23 of the *NSD1* gene changes the cysteine residue at position 2175 to serine. This finding is in agreement with the fact that all missense mutations that have been described in Sotos syndrome so far are clustered in conserved functional domains in exons 13, 14, 16, 18, 19, 20, 22, and 23, and that missense mutations outside these domains do not cause SS [2–4]. The clinical findings in our family are consistent with the hypothesis that missense mutations may be associated with a milder outcome in a subset of cases. However, the physical features in our patients are relatively prominent, including marked overgrowth, macrocephaly, and cardiac malformation.

Should the diabetes in patient 3 be considered a chance coincidence, or a rare feature of the SS? To our knowledge, there have been no previous reports on SS and diabetes. Overgrowth and an increased tumor risk are well known features of SS, and one might speculate that both problems are caused by malfunction of growth factors. Abnormal expression of growth factors could increase carbohydrate resistance and thus be diabetogenic, and SS has been associated with endocrine and paracrine alterations in the insulin like growth factor (IGF) system [13]. However, patient 3 was diagnosed with insulin dependent (type 1) diabetes mellitus, which is typically caused by an autoimmune disorder, and with bronchial asthma, representing another immunologically mediated disease. She also had lipedema, the causes of which are unknown. Further observations are needed to understand the possible links between SS and diabetes, asthma, and/or lipedema.

#### Acknowledgements

We thank the participating family members for their help and support.

#### References

- [1] N. Kurotaki, N. Harada, O. Shimokawa, N. Miyake, H. Kawame, K. Uetake, Y. Makita, T. Kondoh, T. Ogata, T. Hasegawa, T. Nagai, T. Ozaki, M. Touyama, R. Shenhav, H. Ohashi, L. Medne, T. Shiihara, S. Ohtsu, Z. Kato, N. Okamoto, J. Nishimoto, D. Lev, Y. Miyoshi, S. Ishikiriyama, T. Sonoda, S. Sakazume, Y. Fukushima, K. Kurosawa, J. Cheng, K. Yoshiura, T. Ohta, T. Kishino, N. Niikawa, N. Matsumoto, Fifty microdeletions among 122 cases of Sotos syndrome: low copy repeats possibly mediate the common deletion, *Hum. Mutat.* 22 (5) (2003) 378–387.
- [2] J. Douglas, S. Hanks, I.K. Temple, S. Davies, A. Murray, M. Upadhyaya, S. Tomkins, H.E. Hughes, T.R.P. Cole, N. Rahman, *NSD1* mutations are the major cause of Sotos syndrome and occur in some cases of Weaver syndrome but are rare in other overgrowth phenotypes, *Am. J. Hum. Genet.* 72 (1) (2003) 132–143.
- [3] M. Rio, L. Clech, J. Amiel, L. Faivre, S. Lyonnet, M. Le Merrer, S. Odent, D. Lacombe, P. Ederly, R. Brauner, O. Raoul, P. Gosset, M. Prieur, M. Vekemans, A. Munnich, L. Colleaux, V. Cormier-Daire, Spectrum of *NSD1* mutations in Sotos and Weaver syndromes, *J. Med. Genet.* 40 (6) (2003) 436–440.
- [4] K. Tatton-Brown, J. Douglas, K. Coleman, G. Baujat, T.R.P. Cole, S. Das, D. Horn, H.E. Hughes, I.K. Temple, F. Faravelli, D. Waggoner, S. Türkmen, V. Cormier-

- Daire, A. Irrthum, N. Rahman, Genotype–phenotype associations in Sotos syndrome: an analysis of 266 individuals with NSD1 aberrations, *Am. J. Hum. Genet.* 77 (2) (2005) 193–204.
- [5] N. Huang, E. vom Baur, J.M. Garnier, T. Lerouge, J.L. Vonesch, Y. Lutz, P. Chambon, R. Losson, Two distinct nuclear receptor interaction domains in NSD1, a novel SET protein that exhibits characteristics of both corepressors and coactivators, *EMBO J.* 17 (12) (1998) 3398–3412.
- [6] R. Schneider, A.J. Bannister, T. Kouzarides, Unsafe SETs: histone lysine methyltransferases and cancer, *Trends Biochem. Sci.* 27 (8) (2002) 396–402.
- [7] J.M. Opitz, D.W. Weaver, J.F. Reynolds jr., The syndromes of Sotos and Weaver: reports and review, *Am. J. Med. Genet.* 79 (4) (1998) 294–304.
- [8] F.J. Hansen, B. Friis, Familial occurrence of cerebral gigantism, Sotos' syndrome, *Acta Paediatr. Scand.* 65 (3) (1976) 387–389.
- [9] P. Höglund, N. Kurotaki, S. Kytölä, N. Miyake, M. Somer, N. Matsumoto, Familial Sotos syndrome is caused by a novel 1 bp deletion of the NSD1 gene, *J. Med. Genet.* 40 (1) (2003) 51–54.
- [10] M.M. van Haelst, J.J.M. Hoogeboom, G. Baujat, H.T. Brüggewirth, I. Van de Laar, K. Coleman, N. Rahman, M.F. Niermeijer, S.L.S. Drop, P.J. Scambler, Familial gigantism caused by an NSD1 mutation, *Am. J. Med. Genet.* 139A (1) (2005) 40–44.
- [11] S. Tei, S. Tsuneishi, M. Matsuo, The first Japanese familial Sotos syndrome with a novel mutation of the NSD1 gene, *Kobe J. Med. Sci.* 52 (1–2) (2006) 1–8.
- [12] S. Türkmen, G. Gillessen-Kaesbach, P. Meinecke, B. Albrecht, L.M. Neumann, V. Hesse, S. Palanduz, S. Balg, F. Majewski, S. Fuchs, P. Zscheschang, M. Greiwe, K. Mennicke, F.R. Kreuz, H.J. Dehmel, B. Rodeck, J. Kunze, S. Tinschert, S. Mundlos, D. Horn, Mutations in *NSD1* are responsible for Sotos syndrome, but are not a frequent finding in other overgrowth phenotypes, *Eur. J. Hum. Genet.* 11 (11) (2003) 858–865.
- [13] L. de Boer, H.A. van Duyvenvoorde, E.C. Willemstein-van Hove, C.M. Hoogerbrugge, J. van Doorn, J.A. Maassen, M. Karperien, J.M. Wit, Mutations in the NSD1 gene in patients with Sotos syndrome associate with endocrine and paracrine alterations in the IGF system, *Eur. J. Endocrinol.* 151 (3) (2004) 333–341.