

HIGH RESOLUTION UNENHANCED COMPUTED TOMOGRAPHY IN PATIENTS WITH SWOLLEN LEGS

E.D. Monnin-Delhom, B.P. Gallix, C. Achard, J.M. Bruel, C. Janbon

Service d'Imagerie Medicale (EDM-D,BPG,CA,JMB) and Service de Medecine Interne (CJ), Saint Eloi Hospital, Montpellier, France

ABSTRACT

Purpose: To evaluate the accuracy of computed tomography (CT) scan imaging in distinguishing lymphedema from deep venous thrombosis (DVT) and lipodystrophy (lipedema) in patients with swollen legs.

Material and Methods: CT scans of the lower limbs were performed in 55 patients with 76 swollen legs (44 lymphedemas, 12 DVT and 20 lipedemas). Thirty-four normal contralateral legs were also similarly evaluated. Primary lymphedema was verified by lymphography or lymphoscintigraphy, whereas secondary lymphedema was documented by a typical clinical history. DVT was established by ultrasound Doppler imaging. The diagnosis of lipedema was made with bilateral swollen legs where lymphoscintigraphy and Doppler examination were both unremarkable. Qualitative CT analysis was based on skin thickening, subcutaneous edema accumulation with a honeycombed pattern, and muscle compartment enlargement.

Results: Sensitivity and specificity of CT scan for the diagnosis of lymphedema was 93 and 100%, respectively; for lipedema it was 95 and 100%, respectively; and for DVT it was 91 and 99%, respectively. Skin thickening was found in 42 lymphedemas (95%), in 9 DVT (75%), and in 2 lipedemas (16%). Subcutaneous edema accumulation was demonstrated in 42 legs (95%) with lymphedema and in 5

(42%) with DVT but in none with lipedema. A honeycombed pattern was present only in lymphedema (18 legs or 41%); muscle enlargement was present in all patients with DVT, in no patient with lipedema, and in 4 (9%) with lymphedema.

Conclusion: Edema accumulation is readily demonstrated with plain CT scan and is not present in lipedema. Specific CT features of the subcutaneous fat and muscle compartments allow accurate differentiation between lymphedema and DVT.

Lymphedema, lipodystrophy (lipedema), and deep venous thrombosis (DVT) are common causes of swelling of the lower limb. Because treatment differs among these entities, differential diagnostic distinction is important. Clinical assessment alone to distinguish among these etiologies can be difficult and especially between lymphedema and lipedema. CT is a non-invasive method which potentially can define the patterns and localize edema to the different compartments of a limb.

Lymphedema relates to insufficiency or obstruction of the lymphatic system, and is typically classified as primary or secondary. Primary lymphedema is a congenital maldevelopment of the lymphatic system whereas secondary lymphedema is the aftermath of damage or obstruction to the lymphatic drainage system. Invasive procedures such as direct lymphography

(incision) or lymphoscintigraphy (puncture) are generally considered the gold standard diagnostic methods for investigation of lymphatic transport disorders (1).

Lipedema is a term often used for an abnormal deposit of subcutaneous fat (lipodystrophy). The pathogenesis is still unclear, but lipedema is not the consequence of venous or lymphatic insufficiency (2). The clinical diagnosis can be confusing and it is frequently mistaken for other causes of lower limb swelling including lymphedema.

Deep venous thrombosis is a common cause of acute leg swelling and the diagnosis is nowadays usually confirmed by venography or Doppler sonography which substantiates venous blockage.

The aim of the present study was to evaluate the accuracy of plain CT imaging for differentiating lymphedema, lipedema, and DVT in patients with a swollen lower limb.

MATERIALS AND METHODS

Fifty-five consecutive patients undergoing CT imaging to evaluate unilateral or bilateral swollen legs (from September 1996 to March 1999). There were 15 males and 40 females with an average age of 49 years (range 16-91 years). The swelling was unilateral in 34 patients and bilateral in 21. A total of 110 legs was divided into two groups: group A comprised 76 swollen legs and group B comprised 34 normal contralateral legs. Group A patients included 44 with lymphedema, 12 with deep venous thrombosis, and 20 with lipedema. Primary lymphedema (33 limbs in 23 patients) was confirmed by bilateral direct lymphography (2 patients) or bilateral lymphoscintigraphy (21 patients); lymphatic insufficiency was bilateral in 10 and unilateral in 13 patients. Secondary lymphedema (11 legs) was based on a typical clinical history; that is, surgical resection of malignant tumors with or without radiotherapy in six patients (two melanomas, two cervix epitheliomas, one testicular and one bladder cancer) and surgery for a benign

mass in four patients (one ovarian teratoma, two inguinal adenitis, and one lipoma); secondary lymphedema was bilateral in one patient (bladder cancer).

The diagnosis of DVT was established by Doppler sonography. The diagnosis of lipedema was based on clinical findings of obesity, normal lymphoscintigraphy and normal sonographic assessment of the deep and superficial venous systems.

The control legs were considered normal on the basis of the clinical history, physical examination, and the normal results of both ultrasound and lymphoscintigraphic examinations.

Patients were examined in a Somatom DRH CT unit (Siemens Medical Systems, Erlangen, Germany). High resolution millimetric axial slices (240Mas, 120KV) at 30 mm intervals were obtained from the top of the thigh to the ankle (20 slices) without intravenous contrast medium. The patients did not wear compression bandages during the scan. The CT scans were blindly reviewed by the same radiologist.

First, a qualitative analysis of the CT scan was performed, based on assessment of the skin, the subcutaneous fat, and the muscle compartment. The following criteria, based on our experience and literature data, were studied: skin thickening, subcutaneous edema, and muscle compartment enlargement. Skin thickening was defined as direct visualization of a hyperdense line at the level of the skin. Subcutaneous edema was defined as "infiltration" of the subcutis by soft-tissue densities bands, trabeculae or collection. The dependent or non-dependent location of the edema was noted. A "honeycombed sign" was defined as subcutaneous fat stranding with trabeculae both parallel and perpendicular to the dermis. The muscle compartment was considered enlarged as compared with the contralateral leg.

Second, in order to evaluate the sensitivity and specificity of CT for assessing the cause of a swollen limb, the CT diagnosis was assessed as following: lymphedema was

TABLE 1
CT Features in Lymphedema, DVT, and Lipedema

Clinical State	n	Skin Thickening	Subcutaneous Edema			Muscle Enlargement
			Dependent	Non-Dependent	Honeycombed Pattern	
Lymphedema	44	42 (95)*	0	42 (95)	18 (41)	4 (9)
Deep Venous Thrombosis	12	9 (75)	4	1	0	12 (100)
Lipedema	20	2 (16)	0	0	0	0
Normal	34	0	0	0	0	0

*Numbers in parenthesis=%

diagnosed when skin thickening and subcutaneous edema were noted; DVT was diagnosed when there was prominent muscle enlargement, with or without skin thickening and subcutaneous edema but without a honeycombed pattern. Lipedema (obesity) was diagnosed with symmetrical bilateral soft tissue enlargement but without either skin thickening or subcutaneous edema. Calculations were based on the findings in each leg.

RESULTS

CT features are summarized in *Table 1*. Subcutaneous edema in lymphedema was uniformly in the non-dependent position (*Fig. 1*). A honeycombed pattern seen in lymphedema was not present in DVT or lipedema (*Fig. 2*). No subcutaneous or muscle edema was seen in lipedema (*Fig. 3*).

There was enlargement of the muscle compartment in all DVT related leg edema (*Fig. 4*). The sensitivity and specificity of CT were respectively 97% and 100% for the diagnosis of lymphedema, 98% and 100% for the diagnosis of DVT, 100% and 95% for the diagnosis of lipedema. The two false

negatives in lymphedema were related to misdiagnoses of "normal" leg (one patient) and "lipedema" (one patient). Two DVT related edemas were misdiagnosed as "normal."

DISCUSSION

Chronic swelling of a lower limb is a common condition. Distinguishing lymphedema, "lipedema," or obesity, and DVT-related edema can be clinically difficult. Nonetheless, the distinctions are critical for treatment. For example, a patient with DVT needs prompt anticoagulation, one with lymphedema can be improved with operation or non-operative physiotherapy (3). On the other hand, bandaging and manual drainage are inappropriate for a patient with lipedema.

The three conditions each have a different pathogenesis and the distribution of the fluid/fat in the skin, subcutaneous tissue, and muscle compartment is different. Axial CT slices analyze separately these 3 compartments allowing qualitative evaluation and localizing of the site of edema if present. For the diagnosis of lymphedema, based on CT demonstration of skin thickening and

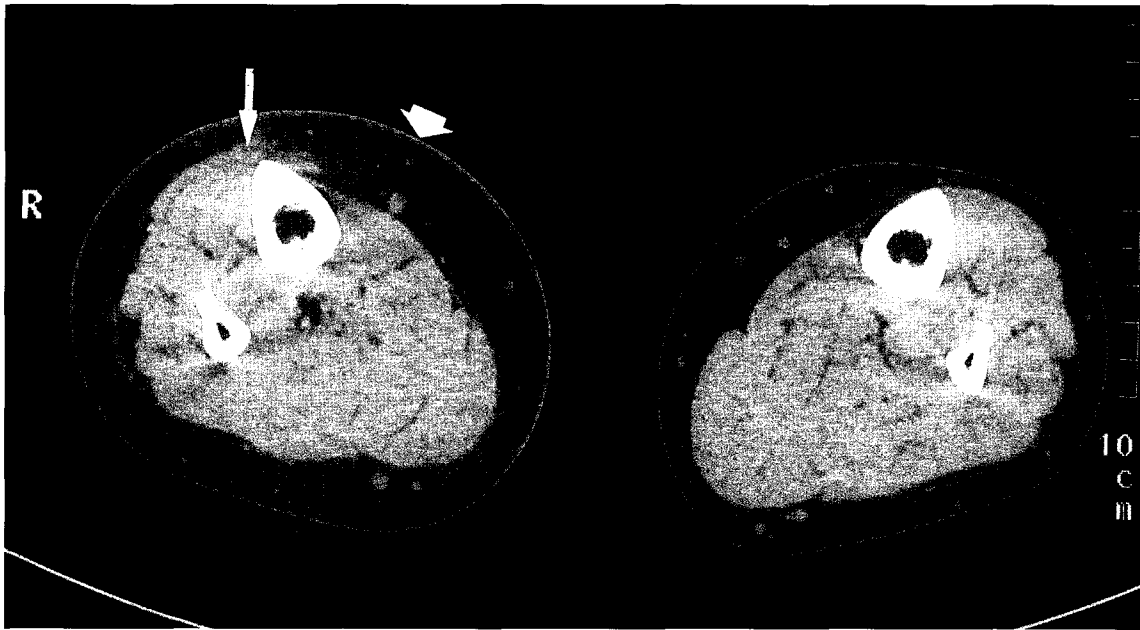


Fig. 1. Unenhanced CT scan of unilateral lymphedema of the right lower limb. Skin thickening (large solid arrow) with subcutaneous fat infiltration (trabeculae underlying parallel to the dermis and perimuscular collection in a non-dependent location) (small solid arrow).

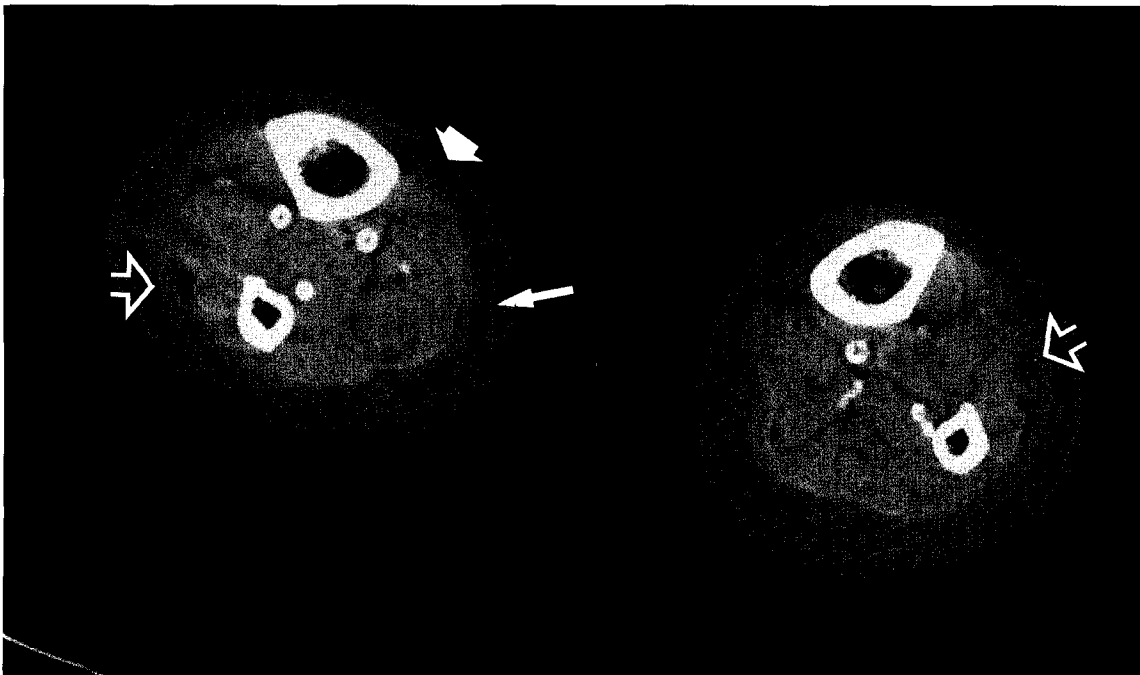


Fig. 2. Unenhanced CT scan of bilateral lymphedema of the lower limb. Skin thickening (large solid arrow) with honeycombed pattern (small solid arrow) and collections (open arrow).

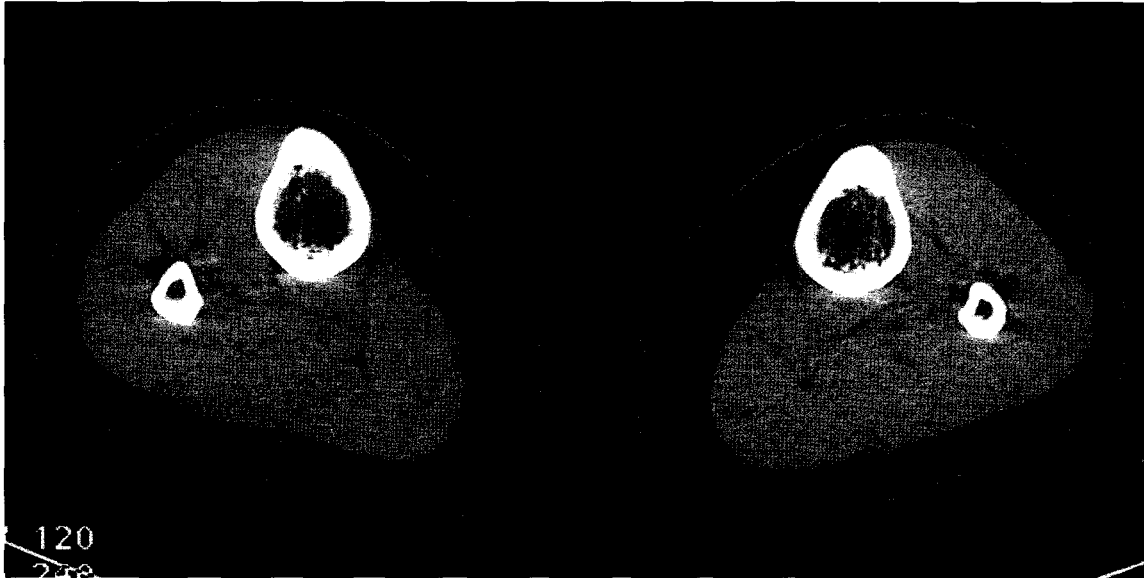


Fig. 3. Unenhanced CT scan of bilateral lipodystrophy of the lower limbs. Bilateral subcutaneous enlargement without skin thickening nor subcutaneous fat infiltration.

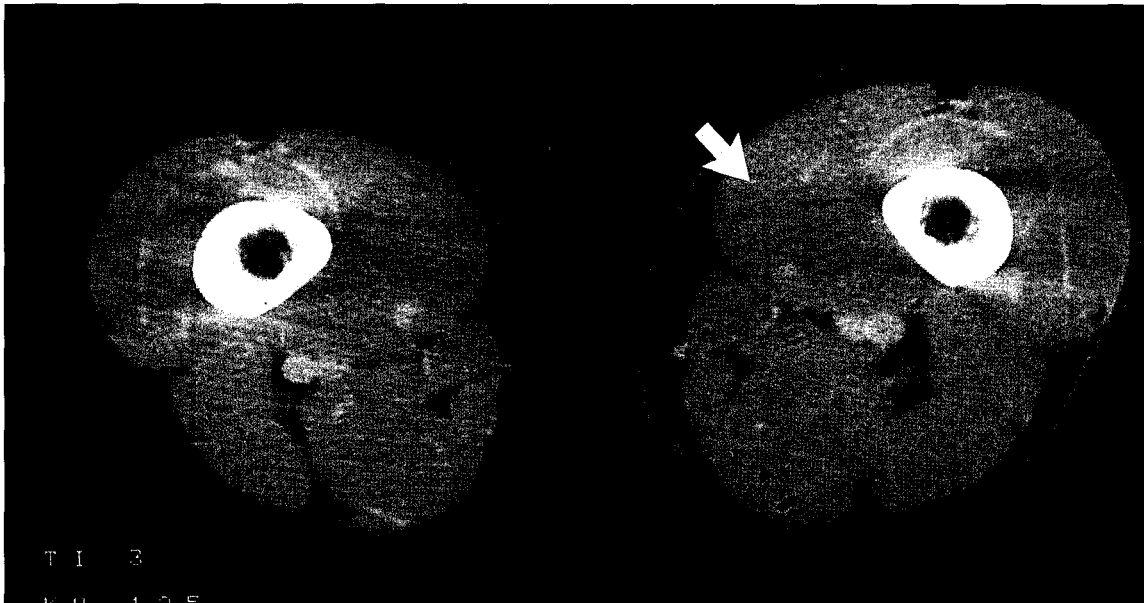


Fig. 4. CT scan of the thighs with left femoral thrombosis. Enlargement of the left muscle compartment (large solid arrow).

subcutaneous non-dependent edema, the CT sensitivity was 97% with two false negatives. One false negative related to a minimally developed lymphedema with clinical

involvement limited to the foot. This patient was misdiagnosed as normal. A second false negative occurred in a young woman with congenital hemitorso dysmorphia who

developed secondary lymphedema in the hypertrophic leg related to ovarian mass compression. On initial analysis, skin and fat edema were not identified and the patient was wrongly diagnosed as "lipedema." Retrospective examination of the CT images led to the correct diagnosis and a lymphoscintigram showed minimal delay in lymphatic transport. A CT scan specificity for lymphedema is high: 100%. Thus, a non-dependent honeycombed pattern was found only in lymphedema.

Previous studies in patients with lymphedema have also described skin thickening (4-8) and subcutaneous fat hypertrophy (9). A major role of lymphatics is to drain extracellular fluid and macromolecules away from the interstitium (10,11). In normal limbs, these entities can drain unimpeded but with lymphatic insufficiency they accumulate in the extracellular space (12).

Skin thickening has been also described with sonography and MR imaging. Using a 20 MHz transducer, high resolution sonography has demonstrated an overload of fluid in the superficial and deep dermis in patients with lymphedema (13). A precise analysis of intact skin can also be performed with high resolution MR imaging depicting the epidermis, the dermis and the subcutis (14). MR imaging shows skin thickening, an increased volume of subcutaneous fat lobules (15), and a circumferential, diffuse or reticular pattern of the subcutaneous edema.

The constant non-dependent location of the subcutaneous edema we have documented (*see Fig. 1*) has not been described previously. Edema due to lymph stasis is rich in high weight macromolecular proteins and is distinctly different from a subcutaneous edema related to increased hydrostatic pressure (e.g., heart failure). This difference probably explains why edema from lymph stasis can coagulate as a gel, and in a short time examination in the decubitus position in our scanning protocol (10-15 min) favors a non-dependent location for the edema.

A honeycombed subcutaneous edema

pattern is often considered as specific to lymphedema (*see Fig. 2*). It is not found in lipodystrophy (lipedema) or in edema of venous origin. Several hypotheses may explain this peculiar trabeculae formation (16). It is unlikely related to normal or dilated lymphatic vessels (17,18) because a honeycombed pattern is present in primary lymphedema with hypoplastic lymphatics. According to Vaughan, it may relate to chronic inflammation with an influx of macrophages and collagen laid down by fibroblasts (19). Whereas this explanation is feasible, these fluid densities can be reversed as we previously observed after complex physiotherapy (20). Thus, a honeycombed pattern is not predictive of lymphatic drainage efficacy and does not signify lack of response to treatment (21).

This finding is in agreement with the MR T2-weighted images demonstrating an edematogenic hyperintense signal of honeycomb trabeculae from fluid retention in the fat interlobar spaces (5). The honeycombed pattern does not enhance after i.v. iodinated contrast injection and does not correlate to age of lymphedema, ongoing onset, or intercurrent infection (lymphangitis) (4,22). The edema in lymphedema was primarily localized to the skin and subcutaneous fat, but in four patients there was enlargement in the muscle compartment. CT and MRI studies are not uniformly concordant and in several studies, there has been no statistical difference in CT cross-sectional measurement of the subfascial compartment between the lymphedematous limb and the normal contralateral one (23). Conversely, MRI can show muscle edema with a significant T2 weighted sequence hyperintensity from lymph stasis around deep veins (24). Other studies, however, fail to show muscle involvement except for possible infiltration by adipose tissue (25).

Intraluminal valves are rare in dermal initial lymphatics but are much more numerous in lymphatics of the muscle. Those lymphatics that contain both valves and

smooth muscle cells generate lymph propulsion. Accordingly, lymph stasis is less prominent in muscle than in dermis or hypodermis; moreover, during exercise, the contraction of the adjacent muscles raises interstitial pressure and favors drainage of tissue lymph fluid (26). On the other hand, the increased weight of a lymphedematous limb can lead to muscular work hypertrophy (12).

In our study, the sensitivity of CT scan for the diagnosis of lipodystrophy (lipedema) was 100%. There is no skin, subcutaneous fat or muscle edema because this condition represents an excess only of fat (*see Fig. 3*).

Lipedema is a common cause of bilateral leg enlargement particularly of women. Previously considered as an abnormal deposition of subcutaneous fat with associated edema (27), this disorder is more accurately considered as lipodystrophy without venous or lymph stasis. An edema pattern was not seen in our patients on CT, ultrasound, or MR images. Ultrasound shows homogeneous hypertrophy of subcutaneous fat without fluid or fibrous elements; there is no significant difference in signal intensity between normal limb and lipedema in T1, T2, and post-Gadolinium T1-weighted sequences but only a subcutis size increase from a lipid hypertrophy (22).

In our study, sensitivity and specificity of CT for the diagnosis of DVT related edema was respectively 98% and 100%. We found an enlarged muscle compartment in all patients with DVT; in two false negative scans, the muscle hypertrophy was the only alteration and was not prominent enough to allow a radiological distinction between DVT and normal limb.

The primary abnormalities in DVT are located within the muscle compartment. Skin thickening and moderate dependent edema of the subcutis is seen, but never in a honey-combed pattern and there is no fibrosis (*See Fig. 4*). CT scan is rarely needed for the diagnosis of DVT, and currently sonography is favored over phlebography. DVT occurs in deep intramuscular veins, explaining edema

and enlargement of both subfascial and epifascial compartments. In an acutely swollen leg, a 10% increase of cross-sectional measurement of the muscle compartment suggests deep venous thrombosis if there is no previous trauma with muscle hematoma (19).

In conclusion, a plain CT scan is a useful non-invasive method to distinguish among lymphedema, DVT related edema, and lipodystrophy (lipedema) of the legs.

REFERENCES

1. Proby, CM: Investigation of the swollen limb with isotopic lymphography. *Br. J. Dermatol* 12 (1990), 29-37.
2. Harwood, CA, RH Bull, H Evans, et al: Lymphatic and venous function in lipedema. *Br. J. Dermatol* 134 (1996), 1-6.
3. Campisi, C: Lymphedema: Modern diagnostic and therapeutic aspects. *Intl. Angiology* 18 (1999), 14-24.
4. Hadjis, NS, DH Carr, L Banks, et al: The role of CT in the diagnosis of primary lymphedema of the lower limb. *Am. J. Roentgenol*, 144 (1985), 361-364.
5. Haaverstad, R, G Nilsen, PA Rinck, et al: The use of MRI in the diagnosis of chronic lymphedema of the lower extremity. *Intl. Angiology* 13 (1994), 115-118.
6. Cox, NH, WD Paterson, AW Popple: A reticulate vascular abnormality in patients with lymphedema: observations in eight patients. *Br. J. Dermatol.* 135 (1996), 92-97.
7. Mortimer, PS, GW Cherry, RL Jones, et al: The importance of elastic fibres in skin lymphatics. *Br. J. Dermatol.* 108 (1983), 561-566.
8. Schneider, I, F Czako: Histologic studies on the skin of patients with recurrent erysipelas. *Dermatol. Monasschrift* 15 (1972), 173-180.
9. Marotel, M, R Cluzan, M Pascot, et al: Tomodensitométrie de 150 cas de lymphoedemes des membres inferieurs. *J. Radiol* 79 (1998), 1373-1378.
10. Daroczy, J: Pathology of lymphedema. *Clinics in Dermatology* 13 (1995), 433-444.
11. Casley-Smith, JR: The fine structure and functioning of tissue channels and lymphatics. *Lymphology* 13 (1980), 177-183.
12. Szuba A, SG Rockson: Lymphedema: Anatomy, physiology and pathogenesis. *Vasc. Med.* 2 (1997), 321-326.
13. Gniadecka, M, P Copenhagen: Localization of dermal edema in lipodermatosclerosis,

- lymphedema and cardiac insufficiency. *J. Am. Acad. Dermatol.* 35 (1996), 37-41.
14. Bittoun, J, H Saint James, BG Querleux, et al: In vivo high-resolution MR imaging of the skin in a whole-body system at 1.5 T. *Radiology* 176 (1990), 457-460.
 15. Idy-Peretti, L, J Bittoun, FA Alliot, et al: Lymphedematous skin and subcutis: In vivo high resolution magnetic resonance imaging evaluation. *J. Invest. Dermatol.* 110 (1998), 782-787.
 16. Gamba, JL, PM Silverman, D Ling et al: Primary lower extremity lymphedema: CT diagnosis. *Radiology* 149 (1983), 218.
 17. Fuji, K: MR imaging of edematous limbs in lymphatic and non lymphatic edema. *Acta Radiol.* 35 (1994), 262.
 18. Case, TC, CL Witte, MH Witte, et al: MRI in human lymphedema. Comparison with lymphoscintigraphy. *Magn. Reson. Imaging* 10 (1992), 549.
 19. Vaughan, BF: CT of swollen legs. *Clinical Radiology* 41(1990), 24-30.
 20. Monnin-Delhom, B, MY Evrard, IM Bruel, et al: CT assessment of the efficacy of lymphatic drainage. *Lymphology* 31 (suppl) (1998), 335-339.
 21. Monnin-Delhom E, MY Evrard, IM Bruel, et al: Predictive CT criteria of response to lymphatic drainage in lymphedema of the lower limbs. *Lymphology* 31 (suppl) (1998), 330-334.
 22. Dimakakos, P, T Stefanopoulos P Antoniadis, et al: MRI and ultrasonographic findings in the investigation of lymphedema and lipedema. *Int. Surg* 82 (1997), 411-416.
 23. Collins, CD, PS Mortimer, H D'Ettore, et al: Computed tomography in the assessment of response to limb compression in unilateral lymphoedema. *Clinical Radiology* 50 (1995), 541-544.
 24. Duewell, S, KD Hagspiel, J Zuber, et al: Swollen lower extremity: Role of MR imaging. *Radiology* 184 (1992), 227-231.
 25. Insua, EM, J Vinao, V Martinez: Magnetic resonance imaging of peripheral lymphedema. *Lymphology* 30 (1997), 24-25.
 26. Koschima, I, S Kawada, T Moriguchi, et al: Ultrastructural observations of lymphatic vessels in lymphedema in human extremities. *Plastic and Reconstructive Surg.* 97 (1996), 397-405.
 27. Allen, EU, EA Hines: Lipoedema of the legs. A syndrome characterized by fat legs and orthostatic oedema. *Proc. Staff Mayo Clinic* 15 (1940), 1984-1987.

Elisabeth Monnin-Delhom, M.D.
Service d'Imagerie Medicale
CHU Saint Eloi
80, avenue Augustin Fliche
34295 Montpellier Cedex 5, France
Phone: (33) 4 67 33 71 19
Fax: (33) 4 67 33 75 49
E-mail: e-monnin@chu-montpellier.fr